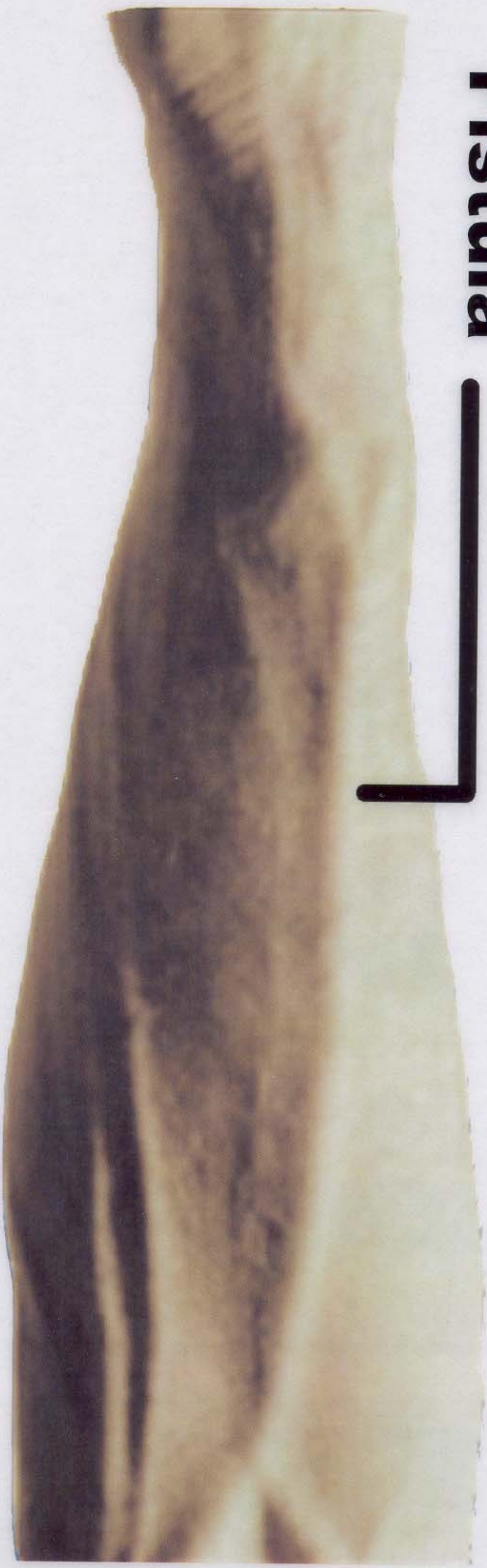


Mature Fistula



This fistula was placed in the patient's forearm.